

Clinical consensus statement: Diagnosis and management of nasal valve compromise

John S. Rhee, MD, MPH, Edward M. Weaver, MD, MPH, Stephen S. Park, MD, Shan R. Baker, MD, Peter A. Hilger, MD, J. David Kriet, MD, Craig Murakami, MD, Brent A. Senior, MD, Richard M. Rosenfeld, MD, MPH, and Danielle DiVittorio, Milwaukee, WI; Seattle, WA; Charlottesville, VA; Livonia, MI; Minneapolis, MN; Kansas City, KS; Chapel Hill, NC; Brooklyn, NY; and Alexandria, VA

Sponsorships or competing interests that may be relevant to content are disclosed at the end of this article.

ABSTRACT

OBJECTIVE: To create a clinical consensus statement to address ambiguities and disparities in the diagnosis and management of nasal valve compromise (NVC).

SUBJECTS AND METHODS: An updated systematic review of the literature was conducted. In addition, a Modified Delphi Method was used to refine expert opinion and facilitate a consensus position.

RESULTS: After two rounds of surveys and conference calls, 36 items reached consensus, six items reached near consensus, and 10 items reached no consensus. The categories that had the greatest percentage of consensus or near consensus items were as follows: definition, history and physical examination, outcome measures, and management. Conversely, the categories with greater percentage of no consensus items were adjunctive tests and coding.

CONCLUSION: The consensus panel agreed that NVC is a distinct clinical entity that is best evaluated with history and physical examination findings. Endoscopy and photography are useful but not routinely indicated, whereas radiographic studies are not useful in evaluating NVC. Other objective nasal outcome measures may not be useful or accepted for NVC. Nasal steroid medication is not useful for treatment of NVC in the absence of rhinitis, and mechanical treatments may be useful in selected patients. Surgical treatment is the primary mode of treatment of NVC, but bill coding remains ambiguous and confusing.

© 2010 American Academy of Otolaryngology–Head and Neck Surgery Foundation. All rights reserved.

Nasal valve compromise (NVC) is a distinct and primary cause of symptomatic nasal airway obstruction, yet there remain ambiguities and disparities in the diagnosis and management. Other etiologies for nasal airway obstruction, either structural or inflammatory, may coexist or mimic the symptoms caused by NVC. Furthermore, current procedural

terminology (CPT) billing coding schemes for nasal valve surgery are unclear, as are the boundaries and overlap with other nasal surgical codes.

The nasal valve, external and internal components, has been described anatomically as the cross-sectional area of the nasal cavity with the greatest overall resistance to airflow, thus acting as the dominant determinant for nasal inspiration (Fig 1). The external nasal valve is defined as the area in the vestibule, under the nasal ala, formed by the caudal septum, medial crura of the alar cartilages, alar rim, and nasal sill. The internal nasal valve is located approximately 1.3 cm from the nares (nostril opening) and corresponds to the region under the upper lateral cartilages, bound medially by the dorsal septum, inferiorly by the head of the inferior turbinate, and laterally by the upper lateral cartilage (Fig 2). As air enters these narrowed segments, acceleration occurs, leading to a decrease in intraluminal pressure (Bernoulli's principle). This phenomenon tends to collapse the lateral nasal wall, where minor septal deviations, weakened soft tissues, or malformed lateral crura can have a great impact on nasal airflow.

To help organize and disseminate information regarding NVC, this consensus panel was convened by the American Academy of Otolaryngology–Head and Neck Surgery to create a clinical consensus statement (CCS). This document reflects information synthesized from an organized group of expert opinions in a written document with the purpose of reviewing the literature, synthesizing information, and attempting to clarify specific areas of controversy or ambiguity.

A recent systematic review¹ of the existing primary literature assigned an aggregate grade of “observational studies without control” to the present evidence addressing NVC. Because of this relative paucity of strong primary studies in the literature, a CCS (as opposed to a clinical

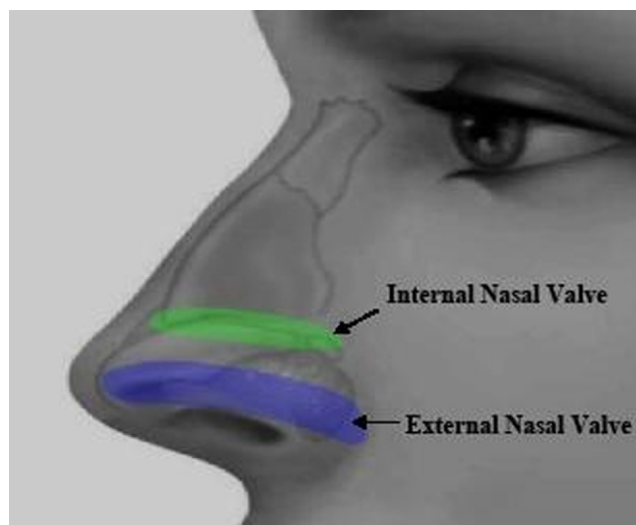


Figure 1 External and internal components of the nasal valve.

practice guideline) was considered appropriate in evaluating this clinical problem. Therefore, the terms evidence-based and guideline are not used in the context of this document, but rather the findings of this consensus panel are stated as opinions or suggestions, not as recommendations. The primary objective was to develop a CCS on NVC with the use of a Modified Delphi Method, which is a rigorous and standardized approach to minimize bias and facilitate consensual position.

Methods

Systematic Review

The recent evidence review on nasal valve repair¹ was used to identify clinically important gaps in knowledge. To ensure full review of the literature, the consensus panel chair (J.S.R.) updated the systematic review using the same search terms and databases as the original review.¹ This updated literature search included articles in PubMed from September 2007 through September 2009. The date criteria were designed to overlap with the initial systematic review, whose authors reviewed the literature published through August 2007. This overlap ensured inclusion of late entries into the literature databases. Only articles published in English were reviewed. No other systematic search limitations were used.

Delphi Method

Overview. The consensus panel used the Delphi Method defined as “a multiple iteration technique usually meant to be anonymous with the purpose of refining the expert opinion and ultimately arrive at a combined or consensual position.”² The original Delphi Method was developed in the 1950s by the RAND Corporation. Over time, the method has been modified and improved, especially with new technology. However, the basic process has remained consistent. The method enables equal input from each panel member and

reduces undue influence of a minority of participants. The CCS development process (Fig 3) consisted of the following:

1. Expert Panel appointment and CCS methods review.
2. Survey development.
3. Panel Surveys (two). Each round included a teleconference discussion of ambiguous items requiring clarification and repeat of the survey.
4. Analyses and interpretation.

Expert Panel

Eight panel members were selected for their work in related fields and their valued expert opinion. The panel represented a wide cross section of subject matter experts mainly representing facial plastic surgery as well as rhinology, sleep medicine, and general otolaryngology—head and neck surgery. The chair identified and recruited the panel members and sought input in the process from panel members.

After panel recruitment was completed, an introductory teleconference oriented the group to the topic and consensus process. Prior to the call, literature was disseminated electronically to help guide discussion.^{1,3-8} The nasal valve repair systematic review was discussed.¹ A qualitative group survey was conducted first, which consisted of open-ended questions to help determine the focus of the consensus statement. This survey concentrated on areas of controversy, knowledge gaps, variances in practice, and disparities of opinion. Topics for the CCS were brainstormed, reviewed, and refined, including:

1. Definition of NVC
2. History and physical examination findings
3. Role of adjunctive diagnostic testing
4. Outcome measures

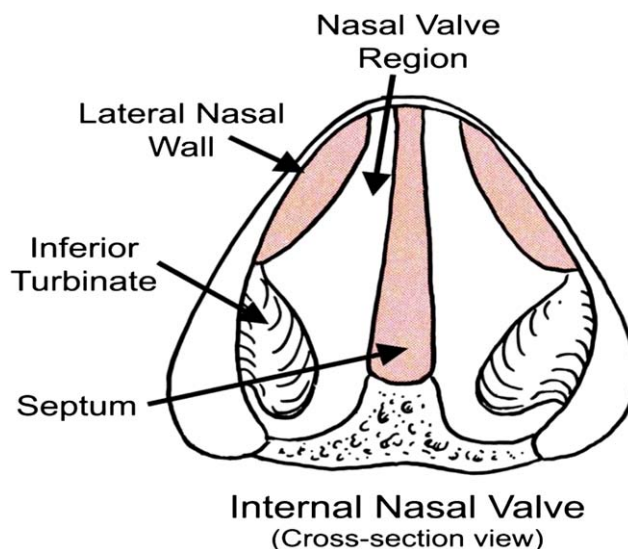


Figure 2 Anatomy of the internal nasal valve.

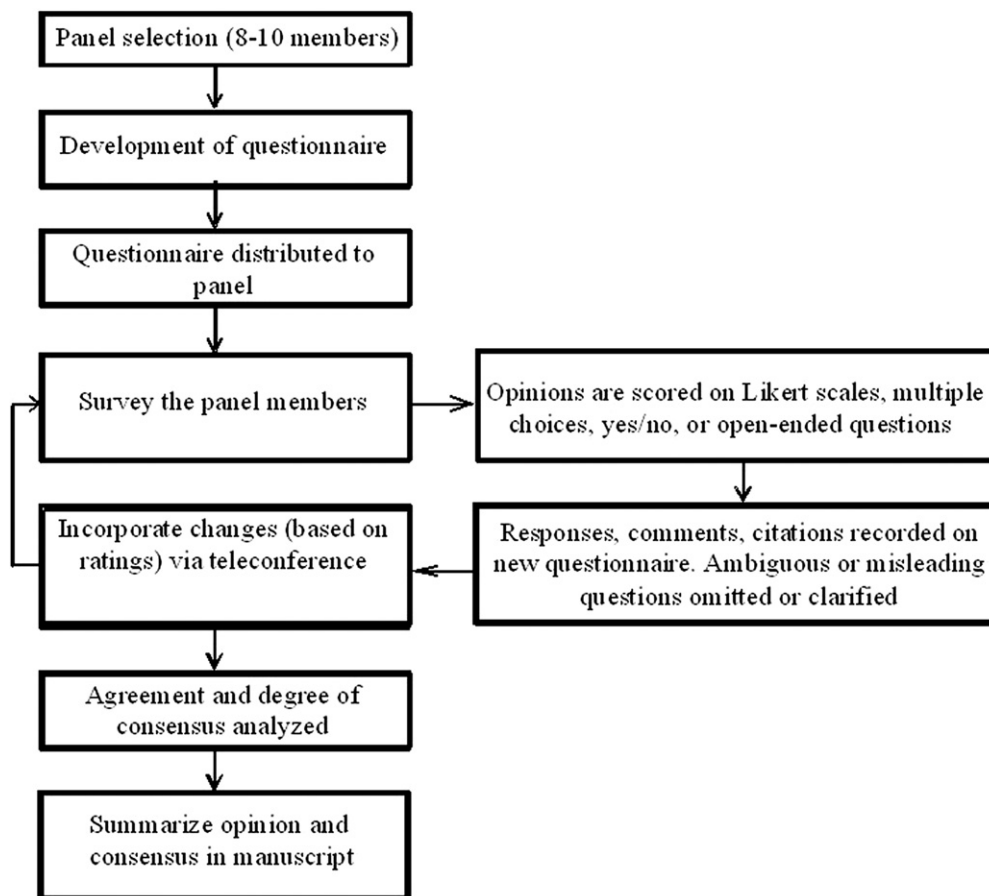


Figure 3 Consensus development process.

5. Management

6. Coding

Survey Development

The first formal survey was developed to cover the aforementioned items. This survey used a qualitative structure with free text responses to open-ended questions that covered the following categories: definition, history and physical examination, adjunctive tests, outcome measures, management, and coding. After reviewing the responses, the chair, in conjunction with a subgroup of the panel, formulated targeted questions on NVC.² To avoid bias, questions were worded in neutral terms. Items were reviewed with the subgroup for content, clarity, and neutrality and were refined as needed. After the first full panel survey, the survey questions were reviewed with the panel for refinement to reduce ambiguity for the second full panel survey.

The survey instrument included statements to which the panel members responded according to their level of agreement on a Likert scale. The nine-point Likert scale ranged from one representing “strongly disagree” to nine representing “strongly agree,” and five was defined as “neutral” (Table 1). Other instrument items required a best response answer (e.g., which would be the most appropriate code for a described procedure). The survey included the published description of each code offered as a choice.⁹

Panel Surveys

The panel was surveyed twice with the use of web-based software (i.e., SurveyMonkey, Menlo Park, CA) to protect confidentiality and to limit the possibility of bias. E-mail addresses were collected strictly for administrative purposes and to track panelist responses; however, all administrative data collected were de-identified before the data were presented to the chair.

Responses were sent to the chair for analysis once each panelist had completed the survey. The responses were then summarized and distributed among the group for review via a conference call. Throughout the process, conference calls were designed to provide the opportunity for the chair and panelists to identify ambiguity in the statements, revise wording, and to answer any outstanding questions about the process. They were also used to reconcile any statements that were found to have no consensus or to be irrelevant.

Analyses and Interpretation

Statistical analyses were performed for each survey question. Likert scales were reported with the mean, mode, median, interquartile range, and full range. The individual items were grouped by the original qualitative survey designation: definition, history and physical examination,

Table 1
Examples of NVC questions and responses on Likert scale

Consensus									
NVC is a distinct clinical entity for patients who present with symptomatic nasal airway obstruction.									
1 Strongly disagree	2	3	4	5 Neutral	6	7	8	9 Strongly agree	Rating average
0	0	0	0	0	0	3	0	5	8.25
Near consensus									
Audible improvement in nasal airflow during a Cottle maneuver (manual lateral retraction of the cheek) or manual intranasal lateralization of the lateral nasal wall is consistent with NVC.									
1 Strongly Disagree	2	3	4	5 Neutral	6	7	8	9 Strongly Agree	Rating average
0	0	0	0	1	1	3	1	2	7.25
No consensus									
Photography is necessary for documenting an external nasal deformity that may be consistent with NVC.									
1 Strongly disagree	2	3	4	5 Neutral	6	7	8	9 Strongly agree	Rating average
1	1	0	0	2	1	1	1	1	5.38

NVC, nasal valve compromise.

adjunctive tests, outcome measures, management, and coding.

For the Likert scales, consensus was defined as responses clustered within two Likert rating points of the mean response with no more than one outlier. Near consensus occurred when there was a cluster around the mean response with two outliers. No consensus was considered when the consensus or near consensus criteria were not met (Table 1).

For the patient scenarios, consensus was reached if an individual response was chosen by at least 75% of the panelists.

Results

Systematic Review

No new original research studies that met search criteria were found during the time period between the systematic

Table 2
Statements within the definition category*

Category	Statement	Mean	Mode	Median	IQR	Range
Consensus	NVC is a distinct clinical entity for patients who present with symptomatic nasal airway obstruction.	8.3	9	9	2	7-9
	NVC can be caused by a wide columella.	7.6	7	7.5	1.5	6-9
	NVC can be caused by collapse of the alar rim or lateral nasal wall, which may be static or associated with inspiration.	8.9	9	9	0	8-9
	NVC can be caused by collapse of the cartilaginous portion of the nasal dorsum.	7.9	8, 9	8	1.5	5-9
	NVC can be caused by a high septal deviation.	8.8	9	9	0.5	8-9
	NVC can be caused by a hypertrophied inferior turbinate.	7.3	7	7.5	1.5	7-9
	NVC can be caused by a severely ptotic nasal tip.	7.9	7	7.5	2	7-9
	NVC can be caused by a caudal septal deflection.	8.3	8, 9	7.5	2	7-9
Near consensus	N/A	N/A	N/A	N/A	N/A	N/A
No consensus	NVC can be caused by an inferior septal spur.	5.5	1, 7, 9	6	5.5	1-9

IQR, interquartile range; NVC, nasal valve compromise; N/A, not applicable.

*All data based on a nine-point Likert scale of agreement with the statement, where 1 = strongly disagree, 5 = neutral, and 9 = strongly agree.

review¹ and this CCS document; however, one additional systematic review was found and reviewed.¹⁰

Survey Results

After the qualitative portion of the survey design was completed, a total of 53 questions were created and administered. After the first panel survey, 27 items reached consensus, nine items reached near consensus, and 17 items reached no consensus. After the review, survey revision, and second panel survey, 36 items reached consensus, six items reached near consensus, and 10 items reached no consensus (Tables 2-7). The categories that had the greatest percentage of consensus or near consensus items were definition, history and physical examination, outcome measures, and management. Conversely, the categories with a greater percentage of no consensus items were adjunctive tests and coding.

Definition

Consensus was achieved with agreement or strong agreement that NVC is a distinct clinical entity separate from

other anatomic reasons for nasal obstruction. The panel met consensus with agreement or strong agreement that NVC can be caused by collapse of the alar rim or lateral nasal wall, collapse of the cartilaginous portion of the nasal dorsum, a high septal deviation, hypertrophied inferior turbinate, severely ptotic nasal tip, wide nasal columella, and a caudal septal deviation (Table 2). The panel did not meet consensus on whether an inferior septal spur can cause NVC, with scores ranging from strongly disagree to strongly agree.

History and Physical

The panel met consensus with strong agreement that the main symptom of NVC is decreased airflow as reported by the patient and with agreement that NVC can adversely affect sleep (Table 3). The panel also met consensus with agreement or strong agreement with the following: anterior rhinoscopy can be adequate for an intranasal evaluation of the nasal valve, weak or malformed nasal cartilages can be diagnosed on physical examination, inspiratory collapse of the lateral nasal wall or alar rim is consistent with NVC, and

Table 3
Statements within the history and physical examination category*

Category	Statement	Mean	Mode	Median	IQR	Range
Consensus	The main symptom of NVC is decreased nasal airflow as reported by the patient.	8.8	9	9	.5	8-9
	NVC can adversely affect sleep.	7.6	7	7.5	1.5	6-9
	Abnormalities of the lateral nasal wall related to weak or malformed upper lateral and/or weak lower lateral cartilages can be diagnosed by the clinician on physical exam.	8.6	9	9	1	8-9
	Visible inspiratory collapse of the lateral nasal wall is consistent with the diagnosis of NVC.	8.3	9	8.5	1.5	7-9
	Anterior rhinoscopy (no endoscope) can be adequate for an intranasal evaluation of the nasal valve.	8.6	9	9	1	8-9
	Visible inspiratory collapse of the alar rim is consistent with the diagnosis of NVC.	8.1	8, 9	8	1.5	7-9
	Subjective improvement in nasal airflow during a Cottle maneuver (manual lateral retraction of the cheek) or manual intranasal lateralization of the lateral nasal wall is consistent with NVC.	7.8	8	8	1	7-9
	Audible in combination with subjective improvement in nasal airflow during a Cottle maneuver (manual lateral retraction of the cheek) or manual intranasal lateralization of the lateral nasal wall is consistent with NVC.	8.1	8	8	.5	7-9
	Increased nasal obstruction associated with deep inspiration is consistent with NVC.	8	8	8	1	7-9
Near consensus	Audible improvement in nasal airflow during a Cottle maneuver (manual lateral retraction of the cheek) or manual intranasal lateralization of the lateral nasal wall is consistent with NVC.	7.3	7	7	2	5-9
No consensus	Increased nasal obstruction associated with deep expiration may be consistent with NVC.	3.3	1, 3, 5	3	3.5	1-6

IQR, interquartile range; NVC, nasal valve compromise.

*All data based on nine-point Likert scale of agreement with the statement, where 1 = strongly disagree, 5 = neutral, and 9 = strongly agree.

Table 4
Statements within the adjunctive tests category*

Category	Statement	Mean	Mode	Median	IQR	Range
Consensus	There is currently a gold standard test to diagnose NVC. [†]	1.9	1	1	1	1-6
	Nasal endoscopy is useful to rule out other reasons for symptomatic nasal obstruction not caused by NVC.	6.9	7	7	.5	3-9
	Photography is useful for documenting an external nasal deformity that may be consistent with NVC.	8.1	9	8.5	1.5	6-9
	A trial of adult nasal strips (e.g., Breathe Right Strips) is useful for confirming the diagnosis of NVC.	6.3	6	6.5	1.5	2-8
	Radiographic studies (CT or MRI) are routinely indicated to rule out other reasons for symptomatic nasal obstruction not caused by NVC. [†]	1.9	1	1	1.5	1-5
	MRI is useful for confirming the diagnosis of NVC. [†]	1.5	1	1	0	1-5
	CT is useful for confirming the diagnosis of NVC. [†]	2.4	1	1.5	3	1-5
Near consensus	Nasal endoscopy can be useful for diagnosing NVC.	6.4	9	8	4	2-9
No consensus	Photography is necessary for documenting an external nasal deformity that may be consistent with NVC.	5.4	5	5.5	4	1-9
	Nasal endoscopy is routinely indicated to rule out other reasons for symptomatic nasal obstruction not caused by NVC.	5	5	5	3.5	2-9
	Radiographic studies (CT or MRI) are useful to rule out other reasons for symptomatic nasal obstruction not caused by NVC.	4.4	4	4	4	1-8
	Acoustic rhinometry can be useful for diagnosing NVC (answer only if you have experience with this test, otherwise leave blank).	2.3	2	2	1	2-3
	Rhinomanometry can be useful for diagnosing NVC (answer only if you have experience with this test, otherwise leave blank).	4	2, 6	4	4	2-6

IQR, interquartile range; *NVC*, nasal valve compromise; *CT*, computed tomography; *MRI*, magnetic resonance imaging.

*All data based on nine-point Likert scale of agreement with the statement, where 1 = strongly disagree, 5 = neutral, and 9 = strongly agree.

[†]The panel met consensus of disagreement with the statement.

increased nasal obstruction associated with deep inspiration is consistent with NVC. The panel met consensus with agreement that, with valve stabilization maneuvers, a combination of audible and subjective improvement or subjective improvement alone were consistent with NVC, and they met near consensus that audible improvement alone was consistent with NVC. Although a majority of panelists disagreed or strongly disagreed that nasal obstruction associated with deep expiration may be consistent with NVC, no consensus was reached because three panelists were neutral or agreed with this statement.

Adjunctive Tests

With regard to adjunctive tests in the evaluation of NVC, there was a consensus strong disagreement that there is currently a gold standard test to diagnose NVC (Table 4). Nasal endoscopy and nasal photography were both deemed

useful but not routinely required. Specifically, the panel met consensus with agreement that nasal endoscopy is useful to rule out other obstructing pathology, but the panel did not meet consensus on whether endoscopy is routinely indicated for this purpose. There was near consensus that nasal endoscopy can be useful for diagnosing NVC. Similarly, the panel met consensus with agreement that nasal photography is useful for documenting an external nasal deformity that may be consistent with NVC, but there was no consensus on whether photography was routinely necessary. There was a consensus of weak agreement that a trial of adult nasal dilator strips (e.g., Breathe Right strips, GlaxoSmithKline, Middlesex, United Kingdom) is useful for confirming the diagnosis of NVC.

There was less enthusiasm about the role of radiographic studies (e.g., computed tomography [CT] or magnetic resonance imaging [MRI]) in the evaluation of NVC. There

Table 5
Statements within the outcome measures category*

Category	Statement	Mean	Mode	Median	IQR	Range
Consensus	More specifically, visual analogue scales are valid patient-reported indicators of a successful intervention.	7.1	7	7	1	5-8
	Patient-reported outcome measures (e.g., satisfaction or QOL scales) are valid indicators of a successful intervention.	7.6	7	7.5	1	7-9
	More specifically, sinonasal-specific QOL scales (such as the NOSE scale) are valid patient-reported indicators of a successful intervention.	8	8	8	1	7-9
Near consensus	Patient-reported outcome measures are more important in measuring success of an intervention rather than existing available objective ones.	7.3	5, 7, 8, 9	7.5	2.5	5-9
	Existing available objective measures are more important in measuring success of an intervention rather than subjective ones. [†]	2.8	1, 3	3	3	1-5
	Patient-reported outcome measures are equally important as existing available objective ones in measuring the success of an intervention.	6.3	7	7	2.5	2-9
No consensus	More specifically, ad hoc patient satisfaction questionnaires are valid patient-reported indicators of a successful intervention.	6.1	6	6	1	5-8

IQR, interquartile range; *QOL*, quality of life; *NOSE*, Nasal Obstruction Symptom Evaluation.

*All data based on nine-point Likert scale of agreement with the statement, where 1 = strongly disagree, 5 = neutral, and 9 = strongly agree.

[†]The panel met near consensus of disagreement with the statement.

was consensus with strong disagreement that radiographic studies are routinely indicated to rule out other reasons for symptomatic nasal obstruction not caused by NVC, but there was no consensus about whether radiographic studies are useful for this purpose. There was consensus of strong disagreement that MRI is useful for confirming the diagnosis of NVC, and there was no consensus but general disagreement that CT scan is useful for this purpose.

The two items in the adjunctive test category that relate to acoustic rhinometry and rhinomanometry were the only items that did not have a 100 percent response rate. Only two of the eight panelists responded to these items, which had the caveat of “answer only if you have experience with this test, otherwise leave blank.” Because of this low response rate, these two items were categorized in the no-consensus group regardless of score pattern.

Outcome Measures

The panel met consensus with general agreement that various patient-reported outcomes (e.g., visual analog scales, satisfaction measures, quality-of-life scales) are valid indicators of successful intervention. There was no consensus whether ad hoc patient satisfaction questionnaires are valid

indicators of success (Table 5). The panel met near consensus on three statements about the relative importance of patient-reported outcome measures versus objective measures in measuring success of an intervention, with a general conclusion that patient-oriented outcome measures are more important than objective measures.

Management and Coding

With regard to management of NVC, the panel met consensus of strong disagreement that a trial of nasal steroids is indicated for patients with NVC who do not have allergy symptoms or physical examination findings consistent with rhinitis (Table 6). There was consensus with agreement that nasal strips, stents, or cones can be used therapeutically for NVC for some patients.

The panel met consensus with uniformly strong agreement that a surgical procedure that is targeted to support the lateral nasal wall/alar rim is a distinct entity from procedures that correct a deviated nasal septum or hypertrophied turbinate. There was consensus with agreement that, in some cases, septoplasty and/or turbinate surgery can treat NVC without surgery to support the lateral nasal wall/alar rim. For the patient case scenarios,

Table 6
Statements within the management and coding category*

Category	Statement	Mean	Mode	Median	IQR	Range
Consensus	A surgical procedure that is targeted to support the lateral nasal wall/alar rim is a distinct entity from procedures that correct a deviated nasal septum or hypertrophied turbinate.	9	9	9	0	8-9
	In some cases, septoplasty with or without turbinate surgery can treat NVC without surgery to support the lateral nasal wall/alar rim.	8.3	9	9	1.5	6-9
	In some cases, turbinate surgery alone can treat NVC without surgery to support the lateral nasal wall/alar rim.	7	7	7	1.5	1-9
	An isolated surgical procedure that supports bilateral lateral nasal walls (alar batten grafts, alar rim grafts, suture suspension) is best coded as 30465.	9	9	9	.5	7-9
	Adult nasal strips (e.g., Breathe Right Strips) can be used therapeutically for NVC for some patients.	8.4	9	8.5	1	7-9
	Nasal stents or cones can be used therapeutically for NVC for some patients.	8	8, 9	8	1.5	6-9
	A trial of nasal steroids is indicated for patients with NVC who do not have allergy symptoms or physical exam findings consistent with rhinitis. [†]	1.7	1	1	1.5	5
Near Consensus	N/A	N/A	N/A	N/A	N/A	N/A
No Consensus	N/A	N/A	N/A	N/A	N/A	N/A

IQR, interquartile range; *NVC*, nasal valve compromise; *NA*, not applicable.

*All data based on nine-point Likert scale of agreement with the statement, where 1 = strongly disagree, 5 = neutral, and 9 = strongly agree.

[†]The panel met consensus of disagreement with the statement.

only two of the five coding questions reached consensus of agreement after the Delphi rounds, even though this topic was discussed heavily on the conference calls between the two rounds (Tables 7 and 8).

Discussion

The purpose of this CCS was to help distinguish NVC from other disease entities that may cause symptomatic nasal airway obstruction. Furthermore, it was our desire to distill expert opinions on current diagnosis and management strategies for NVC. Finally, we hoped to uncover areas of ambiguity and disagreement that would set priorities in need of clarification and for future research.

Systematic Review of Literature

In the review by Rhee et al,¹ the majority of studies used an uncontrolled case series study design, with the exception of two well-controlled cohort studies that specifically compared one surgical technique to another (also called “outcomes study design”).¹ Using published evidence-grading

guidelines for evidence grading from A (strongest evidence) to D (weakest evidence),¹¹ the review authors assigned an aggregate grade C for the overall strength of evidence regarding the surgical management of NVC. A grade of C indicates the evidence overall is represented almost exclusively by uncontrolled case series. To clarify, evidence grading speaks to the strength or quality of the study design, but not to the results of a study.

In fact, there appeared to be a consistent finding of beneficial effects of nasal valve surgery in all reviewed studies. The effect size, however, was difficult to quantify as an aggregate given the heterogeneity of the outcome measures. Also, many of the studies had other adjunctive procedures performed concurrently. The impact of these other simultaneous procedures on the correction of nasal airway obstruction (e.g., septoplasty, turbinate surgery, and sinus surgery) could not be separated from those procedures specifically targeted for other components of the nasal valve.

Similar findings and conclusions were presented in another systematic review by Spielmann et al.¹⁰ They reported that nasal valve surgery research is too focused on the technique

Table 7
Management and coding: patient case scenarios

Consensus	A healthy 25-year-old patient has collapse of the right nasal ala with inspiration with a weak lower lateral cartilage on that side. Patient is also noted to have a caudal septal deviation to the right narrowing the right nasal vestibule. The inferior turbinate is normal and nonobstructive. The next step in management would be: trial of nasal steroids, trial of adult nasal strips (e.g., Breathe Right Strips), surgical intervention.		
	Answer options	Response percent	Response count
	Trial of nasal steroids	0.00	0
	Trial of adult nasal strips (e.g., Breathe Right Strips)	25.00	2
	Surgical intervention	75.0	6
	A patient has a curved midvault, deviated nasal bones, deviated septum, normal turbinate size, and symptoms and physical exam findings consistent with NVC. Patient undergoes an external rhinoplasty approach with insertion of bilateral spreader grafts using septal cartilage, septoplasty, bilateral lateral osteotomies and reconstitution of the nasal tip complex using a dome suture and caudal strut. This procedure would be best coded by:		
	Answer options	Response percent	Response count
	30420	87.5	7
	30465 + 20912	12.5	1
Near consensus	If a caudal septoplasty and right alar rim graft using septal cartilage was chosen, how would this be coded?		
	Answer options	Response percent	Response count
	30520 + 30465 with 52 modifier	62.50	5
	30420	12.50	1
	30465 with 52 modifier + 20912	25.0	2
No consensus	A patient has a curved midvault, straight nasal bones, deviated septum, normal turbinate size, and symptoms and physical exam findings consistent with NVC. Patient undergoes an external rhinoplasty approach with insertion of bilateral spreader grafts using septal cartilage, septoplasty, and the reconstitution of the nasal tip complex using a dome suture. This procedure would be best coded by:		
	Answer options	Response percent	Response count
	30465	12.5	1
	30420	50.0	4
	30465 + 20912	37.5	3
	A 65-year-old patient has a severely ptotic nasal tip with bilateral nasal obstruction symptoms. The nasal septum is midline and the turbinates are normal. Raising the ptotic tip on exam creates marked symptomatic relief of the nasal obstruction symptoms. Patient undergoes a nasal procedure that rotates the tip using a septal cartilage caudal strut graft and other tip procedures. No alar rim/batten grafts are placed. This procedure would be best coded by:		
	Answer options	Response percent	Response count
	30420	0	0
	30465 + 20912	62.50	5
	30400 + 20912	37.50	3

rather than patient outcomes. Additionally, they pointed out the deficiencies in the use of objective measures for assessing nasal airflow to evaluate the efficacy of treatment.

The apparent beneficial clinical effect observed consistently across most of the published studies suggests the importance of surgical management for NVC. However, the

Table 8
Current procedural terminology code definitions⁹

Code	Definition
30400	Rhinoplasty, primary; lateral and alar cartilages and/or elevation of nasal tip.
30420	Rhinoplasty, primary; including major septal repair.
30465	Repair of nasal vestibular stenosis (e.g., spreader grafting, lateral nasal wall reconstruction) (30465 is used to report a bilateral procedure. For unilateral procedure, use modifier 52)
20912	Cartilage graft; nasal septum.
30520	Septoplasty or submucous resection, with or without cartilage scoring, contouring replacement with graft.

lack of controlled studies leaves open the possibility that the observed surgical effects were a result of study biases. It is important to be explicit that lack of strong evidence for surgical management is entirely different from evidence that surgery is not helpful. The lack of evidence simply means that it has not been studied rigorously. Currently, there is existing evidence, albeit mostly uncontrolled study designs, that suggests a strong benefit of surgery. In light of this situation where there appears to be an effect consistently across studies, but the strength of those studies is weak, the CCS was deemed an important step to help define and clarify some of the clinical issues.

Delphi Process Outcomes

Consensus was achieved in many areas of concern (i.e., diagnosis, physical examination findings, outcome measures, and general management strategies). The areas with the most ambiguity were the use of adjunctive tests and coding of the procedures, which relate to preauthorizations and payments for services.

The panel strongly agreed that the diagnosis of NVC is mainly a clinical one on the basis of careful history-taking and physical examination findings. External structural nasal abnormalities at the level of the nostril and internal nasal valve must be carefully examined in addition to the intranasal components of the septum, turbinates, and nasal mucosa. Visible inspiratory collapse of the lateral nasal wall or nostril is diagnostic for NVC, though not necessarily always the target for therapy.

As noted previously, slight and subtle anatomic abnormalities of multiple external or internal structures of the nose can contribute to NVC. Depending on the anatomic area of concern, the targeted therapy may not be “lateral nasal wall surgery” (i.e., vestibular stenosis repair, CPT code 30465). NVC can also be managed by septoplasty, turbinate surgery, or rhinoplasty (elevation or modification of the nasal tip or nasal base in areas of nasal airway interface). Similarly, lateral nasal wall surgery (e.g.,

spreader grafts, suspension sutures, alar batton grafts) may be insufficient alone to correct the nasal airway without concomitant turbinate or septal surgery. The clinician should make a judgment, in conjunction with the patient’s preference as to which of the anatomic structures needs to be addressed to best manage NVC based on individual patient factors. This judgment is mainly based upon exam findings coupled with patient-reported symptoms preferably including disease-specific quality-of-life measures or other scales.

Existing adjunctive diagnostic tests are controversial in their usefulness for NVC diagnosis, and this ambiguity is reflected in our Delphi findings for this category. It should be noted that lack of consensus only means there were different levels of agreement about the role of certain tests; it does not mean that any given test is never useful in evaluating NVC. Currently, there is a lack of a “gold standard” objective test for NVC. Some objective measurement tools, such as acoustic rhinometry or rhinomanometry, are not universally available or accepted, and their limitations in terms of clinical usefulness and unfamiliarity have made these tools less appealing to clinicians. The unfamiliarity of these tools was reflected in our panel responses with only two out of the eight panelists having some expertise with these tests. The role of radiographic tests such as CT or MRI is mainly to rule out other disease processes (e.g., sinusitis, nasal polyps, neoplasms) that may impact nasal airflow. Photographic documentation of NVC was noted sometimes to be useful but not necessary to evaluate NVC. The dynamic nature of NVC and the fact that sometimes the external nasal findings are subtle may not lend themselves to photographic capture at the time of the office visit. Finally, nasal endoscopy was thought to be useful, but there were discrepant opinions about whether it is routinely indicated. In contrast, radiographic studies were not considered useful, except possibly to rule out other obstructing lesions when indicated.

The topic of surgical management of NVC, as it relates to the external nasal deformities, was made purposely broad in its scope. The goal of this CCS was not to evaluate the individual procedures that target correction of the nostril opening or lateral nasal wall (e.g., spreader grafts, alar batten grafts, suspension sutures, and other procedures). Nevertheless, our panelists agree that surgical correction of the lateral nasal wall or nostril opening clearly has a role in treating NVC, and it is indicated when septal and/or turbinate surgery is not sufficient alone or are not etiologic factors for the clinical problem of NVC. The use of alternative mechanical stents, such as nasal cones or nasal dilator strips, has a role in some patients as diagnostic and therapeutic strategies. Patients who are poor surgical candidates because of underlying medical comorbidities or those who do not wish to undergo surgery may find the use of these mechanical stents helpful to treat the lateral nasal wall collapse. However, these devices are not always effective. For example, the patient should be made aware that intra-

nasal deformities such as a severely deviated nasal septum or hypertrophied inferior turbinate will not be addressed in the use of these mechanical stents, which may mitigate the effectiveness of the stents.

The confusion over present CPT coding schemes is exemplified by the lack of consensus by our panel in three of the five patient surgery coding scenarios and statements (Table 7). On the conference calls, there was strong consensus on the appropriate surgical procedures that would address the presented patient problem; however, the translation of the procedures to appropriate CPT coding was deemed difficult. This paradox is exemplified in the case noted in the near-consensus group (Table 7). Consensus was reached in the need for concomitant septoplasty and lateral nasal wall repair; however, the actual coding choices were without consensus. Specifically, if a caudal septoplasty and right alar rim graft with septal cartilage was used to treat NVC, there was consensus that the code should include unilateral lateral nasal wall reconstruction (30465-52), but there was confusion about whether it should include septoplasty (30520) or cartilage graft from the nasal septum (20912). Various factors (e.g., local coding practice patterns, individual interpretation of past coding recommendations, and incomplete descriptions of existing codes) appeared to affect coding choices.

Furthermore, this CCS process brought to light other deficiencies of the existing CPT coding schemes for NVC, such as lack of differentiation between functional versus cosmetic-intended procedures and between primary versus revision surgery. A revised coding scheme is suggested that would more accurately depict the surgical maneuvers that are needed to address the multistructural components of the impaired nasal airway caused by NVC.

Another important area of consensus was reached in the topic of the use of nasal steroid spray as it relates to NVC. NVC as noted earlier is a distinct, anatomical, mechanical source for nasal airway obstruction. The routine and required use of nasal steroid spray as a prerequisite for surgical candidacy for NVC is uniformly not recommended by our panelists in the absence of rhinitis. If the history and physical examination are consistent with NVC without rhinitis, the suggested treatment is targeted surgical management (or the use of mechanical stents in selected cases).

Some of the limitations of this study include the relatively small group of experts weighted on the subspecialty of facial plastic surgery, the physician-only based opinions, the intrinsic limitations of the existing body of literature, and the low strength of opinion-based evidence. Nevertheless, this panel represented a diverse set of relevant clinical specialties that focused on the relevance on patients and clinical practice with the use of a rigorous method to measure opinion consensus on topics not fully addressed in the medical literature. We have developed opinions and suggestions as part of this CCS that will hopefully be used by surgeons, training programs, and other health-care stakeholders for the diagnosis and management of NVC.

Future directions for development are wide ranging. Further scientific inquiry into mechanisms of NVC and testing of therapeutic options are needed. Development and testing of objective measures of NVC and treatment outcome will be helpful. Improvement in surgical techniques and mechanical devices will facilitate better patient care. On a more immediate level, understanding of the coding ambiguities and clarification of the coding schemes is needed. For example, a survey of coding practices among a large sample of nasal valve surgeons would serve to test the validity of the coding confusion and ambiguity highlighted in this CCS.

Summary

The panel found that the literature consistently noted the benefit of surgical treatment of NVC, but the evidence relied mostly on uncontrolled studies. The panel generally agreed on the anatomic and functional features that define the distinct clinical entity of NVC, and that it is best evaluated with history and physical examination findings. Endoscopy and photography are useful but not always routinely indicated, whereas radiographic studies are not thought to be useful in evaluating NVC per se. Other objective nasal outcome measures are not routinely used and may not be useful for this particular nasal condition. Nasal steroid medication is not useful for treating NVC in the absence of rhinitis, and mechanical treatments may be useful in selected patients. Surgical treatment is the primary mode of treatment of NVC, but bill coding remains ambiguous and confusing.

Disclaimer

Clinical consensus statements are provided for informational and educational purposes only. They are based on the opinions of carefully chosen expert panels and are promoted as such. The purpose of the expert panel is to synthesize information, along with possible conflicting interpretations of the data, into clear and accurate answers to the question of interest. Clinical consensus statements may reflect uncertainties, gaps in knowledge, opinions, or minority viewpoints, but through a consensus development process, many of the uncertainties are overcome, a consensual opinion is reached and statements are formed. Clinical consensus statements are not clinical practice guidelines and do not follow the same procedures as clinical practice guidelines. Clinical consensus statements do not purport to be a legal standard of care. The responsible physician, in light of all the circumstances presented by the individual patient, must determine the appropriate treatment, diagnosis, and management. Consideration of clinical consensus statements will not ensure successful patient outcomes in every situation. The American Academy of Otolaryngology–Head and Neck Surgery emphasizes that these clinical consensus statements should not be deemed to include all proper diagnosis/management/treatment decisions or methods of

care, or to exclude other treatment decisions or methods of care reasonably directed to obtaining the same results.

Acknowledgments

We gratefully acknowledge the support provided by Jean Brereton, MBA, Milesh Patel, MS, Kristine Schulz, MPH, and the American Academy of Otolaryngology–Head and Neck Surgery.

Author Information

From the Department of Otolaryngology & Communication Sciences, Medical College of Wisconsin (Dr. Rhee), Milwaukee, WI; VA Puget Sound Health-care System, and the Department of Otolaryngology–Head and Neck Surgery, University of Washington School of Medicine (Dr. Weaver), Seattle, WA; Department of Otolaryngology, University of Virginia Health System (Dr. Park), Charlottesville, VA; Center for Facial Cosmetic Surgery, University of Michigan (Dr. Baker), Livonia, MI; Department of Otolaryngology–Head and Neck Surgery, University of Minnesota (Dr. Hilger), Minneapolis, MN; Department of Otolaryngology–Head and Neck Surgery, University of Kansas (Dr. Kriet), Kansas City, KS; Virginia Mason Medical Center (Dr. Murakami), Seattle, WA; Department of Otolaryngology–Head and Neck Surgery, University of North Carolina (Dr. Senior), Chapel Hill, NC; Department of Otolaryngology, SUNY Downstate Medical Center and the Long Island College Hospital (Dr. Rosenfeld), Brooklyn, NY; and American Academy of Otolaryngology–Head and Neck Surgery (Ms. Divittorio), Alexandria, VA.

Corresponding author: John S. Rhee, MD, MPH, Department of Otolaryngology & Communication Sciences, Medical College of Wisconsin, 9200 W. Wisconsin Avenue, Milwaukee, WI 53226-3522.

E-mail address: jrhee@mew.edu.

Author Contributions

John S. Rhee, writer, co-chair; **Edward M. Weaver**, writer; **Stephen S. Park**, writer; **Shan R. Baker**, writer; **Peter A. Hilger**, writer; **J. David Kriet**, writer; **Craig Murakami**, writer; **Brent A. Senior**, writer; **Richard M. Rosenfeld**, writer, consultant; **Danielle DiVittorio**, writer.

Disclosures

Competing interests: **Peter A. Hilger**, consultant: Medtronic-Restore; **Brent A. Senior**, consultant: BrainLab, Gyrus, Medtronic; speaker: Alcon; stockholder: Phytochem, Remedease, Entrigue.

Sponsorships: Funded by the American Academy of Otolaryngology–Head and Neck Surgery (role: study design and conduct; collection, analysis, and interpretation of the data; and writing or approval of the manuscript.)

References

1. Rhee JS, Arganbright JS, McMullin BT, et al. Evidence supporting functional rhinoplasty or nasal valve repair: a 25-year systematic review. *Otolaryngol Head Neck Surg* 2008;139:10–20.
2. Helmer O, Rescher N. On the epistemology of the inexact sciences. *Management Sci* 1959;6:25–52.
3. Mehta AC, Prakash UB, Garland RH, et al. American College of Chest Physicians and American Association for Bronchology [corrected] consensus statement: prevention of flexible bronchoscopy-associated infection. *Chest* 2005;128:1742–55.
4. Rhee JS, Poetker DM, Smith TL, et al. Nasal valve surgery improves disease-specific quality of life. *Laryngoscope* 2005;115:437–40.
5. Baumann MH, Strange C, Heffner JE, et al. AACP Pneumothorax Consensus Group. Management of spontaneous pneumothorax: an American College of Chest Physicians Delphi consensus statement. *Chest* 2001;119:590–602.
6. Shemirani NL, Rhee JS. Nasal airway obstruction: allergy and otolaryngology perspectives. *Ann Allergy Asthma Immunol* 2008;101:593–8.
7. Khosh MM, Jen A, Honrado C, et al. Nasal valve reconstruction: experience in 53 consecutive patients. *Arch Facial Plast Surg* 2004;6:167–71.
8. Hawryluck LA, Harvey WR, Lemieux-Charles L, et al. Consensus guidelines on analgesia and sedation in dying intensive care unit patients. *BMC Med Ethics* 2002;3:E3.
9. Beebe M, Dalton JA, Espronceda M, et al. Current Procedural Terminology 2009 Professional Edition. Chicago, IL: American Medical Association; 2009.
10. Spielmann PM, White PS, Hussain SS. Surgical techniques for the treatment of nasal valve collapse: a systematic review. *Laryngoscope* 2009;119:1281–90.
11. Sackett DL, Richardson WS, Rosenberg W, et al. Evidence-Based Medicine: How to Practice and Teach EBM. London: Churchill Livingstone, Inc; 2000.